


PATIENT PRESENTING CLINICAL SIGNS

PATIENT Zeke Piezon History: ADR past 3 days – lethargy and not wanting to move.

SPECIES Physical Examination: N/A.

Feline Urinalysis: N/A.

CBC: Neutropenia.

BREED Serum Biochemistry: Elevated GGT activity, amylase and lipase.

Siamese Radiographic Findings: N/A.

SEX

FS

Age

14 years

ULTRASONOGRAPHIC EXAMINATION OF THE ABDOMEN
Urinary System

Full urinary bladder with a normal thickness and appearance of the wall. Normal anechoic urine with no sediment or uroliths evident.

WEIGHT Normal trigone area, proximal urethra (0.3 cm), and iliac blood vessels.

Normal iliac lymph nodes. Ureters not visualized.

INTERPRETED BY

Remo Lobetti, BVSc,
MMedVet (Med), PhD, Dipl.
ECVIM

Renomegaly (left 5.7 cm, right 5.2 cm) with increased echogenic appearance, loss of cortico-medullary differentiation, and normal pelvis and capsule.

Reproductive System

N/A.

IMAGING PERFORMED BY

Sonya Myers, DVM

Adrenal Glands

Normal shape, echogenic appearance, size, and position. Left 0.44 cm, right 0.46 cm.

HOSPITAL NAME

Oviedo Veterinary Care and
Emergency

Spleen

Enlarged (1.5 cm) with a diffuse hyperechogenic appearance and irregular capsule. Smooth homogenous parenchyma and normal vasculature. No evidence of inflammatory, neoplastic, infarction, or infiltrative changes noted.

REFERRING VET

Dr Gonzalez

Liver

Enlarged with rounded edges, hypoechogenic appearance, prominent portal markings, and regular curvilinear capsule. No nodules or masses evident. Full gall bladder containing normal anechoic bile. Normal thickness and echogenic appearance of the gall bladder wall. Normal bile duct (0.2 cm).

INVOICE

303405

Gastrointestinal
DATE

9/16/22

Normal appearance of the stomach, duodenum, small intestine, ileo-cecal junction, and colon with no loss of layering, normal wall thickness (duodenum 0.26 cm, jejunum 0.27 cm) and peristaltic activity, and no distension of the lumen.



PATIENT *Pancreas*

Zeke Piezon Enlarged (right 0.5 cm) with a diffuse hypoechoogenic appearance and irregular capsule. Hyperechoogenic appearance of the mesentery and fat surrounding the pancreas.

SPECIES *Free Abdomen*

Feline Mesenteric lymphadenomegaly (1 cm) with a normal shape and echogenic appearance. Small amount of acellular ascites.

BREED Hyperechoogenic and nodular appearance of the mesentery.

Siamese

ULTRASONOGRAPHIC FINDINGS

SEX

Primary Findings:

FS

Age

14 years

WEIGHT

- Pancreatitis.
- Renomegaly.
- Splenomegaly.
- Hepatopathy.
- Lymphadenomegaly.
- Mesenteric inflammation with ascites.

Secondary Findings:

- None.

INTERPRETED BY

Remo Lobetti, BVSc,
MMedVet (Med), PhD, Dipl.
ECVIM

INTERPRETATION OF THE FINDINGS & FURTHER RECOMMENDATIONS

The appearance of the pancreas is consistent with pancreatitis.

IMAGING PERFORMED BY

Sonya Myers, DVM

With the appearance of the kidneys, spleen, liver, lymph nodes and the mesentery; lymphoma, granulomatous disease, and abdominal carcinomatosis would be important differential diagnosis; however, these changes may merely be secondary to the pancreatitis.

HOSPITAL NAME

Oviedo Veterinary Care and
Emergency

Further assessment would be fPL/PSL assay, FNA cytology of the liver, spleen, and mesentery, and analysis of the ascitic fluid.

REFERRING VET

Dr Gonzalez

Specific therapy would be dependent on an etiological diagnosis.

INVOICE

303405

DATE

9/16/22



PATIENT

Zeke Piezon

SPECIES

Feline

BREED

Siamese

SEX

FS

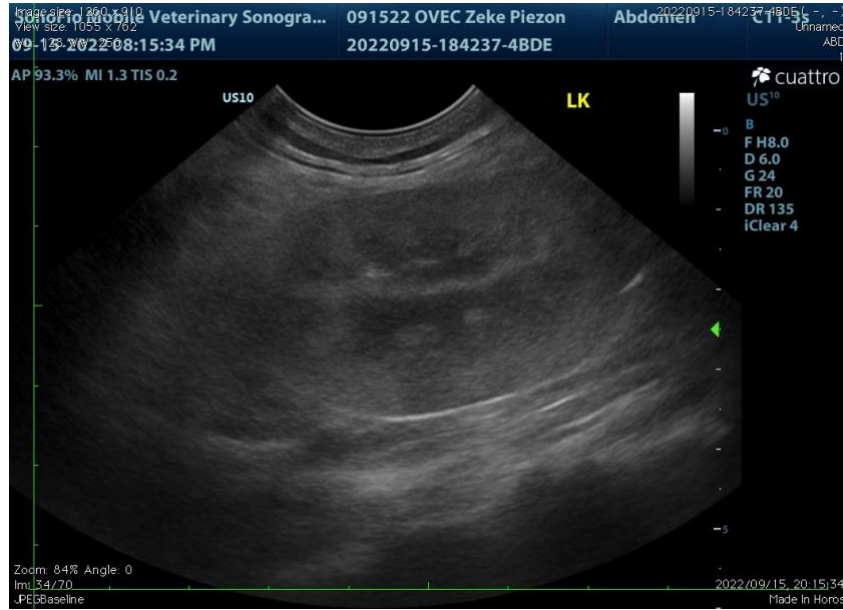
Age

14 years

WEIGHT

IMAGES

Left kidney



INTERPRETED BY

Spleen

Remo Lobetti, BVSc,
 MMedVet (Med), PhD, Dipl.
 ECVIM

IMAGING PERFORMED BY

Sonya Myers, DVM

HOSPITAL NAME

Oviedo Veterinary Care and
 Emergency

REFERRING VET

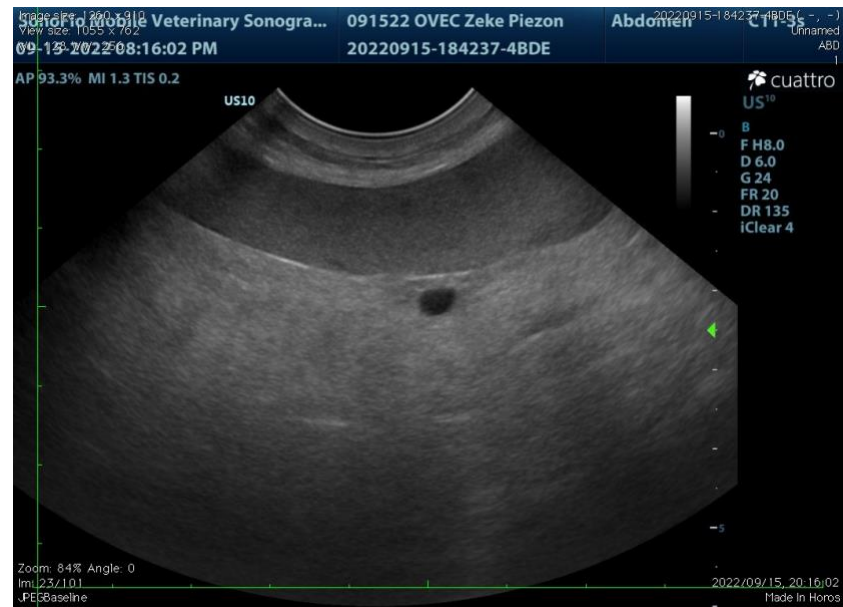Dr Gonzalez

INVOICE

303405

DATE

9/16/22





PATIENT Pancreas

Zeke Piezon

SPECIES

Feline

BREED

Siamese

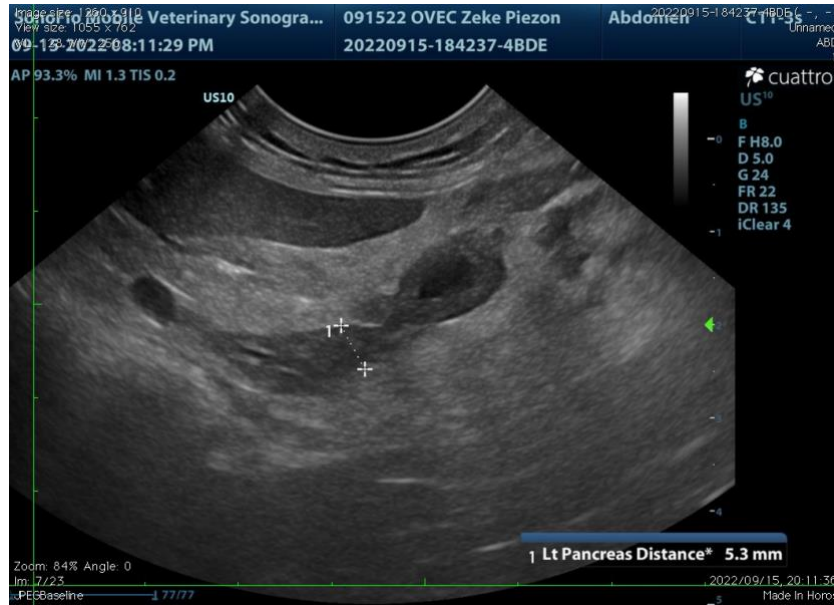SEX

FS

Age

14 years

WEIGHT



Mesentery

INTERPRETED BY

Remo Lobetti, BVSc,
 MMedVet (Med), PhD, Dipl.
 ECVIM

IMAGING PERFORMED BY

Sonya Myers, DVM

HOSPITAL NAME

Oviedo Veterinary Care and
 Emergency

REFERRING VET

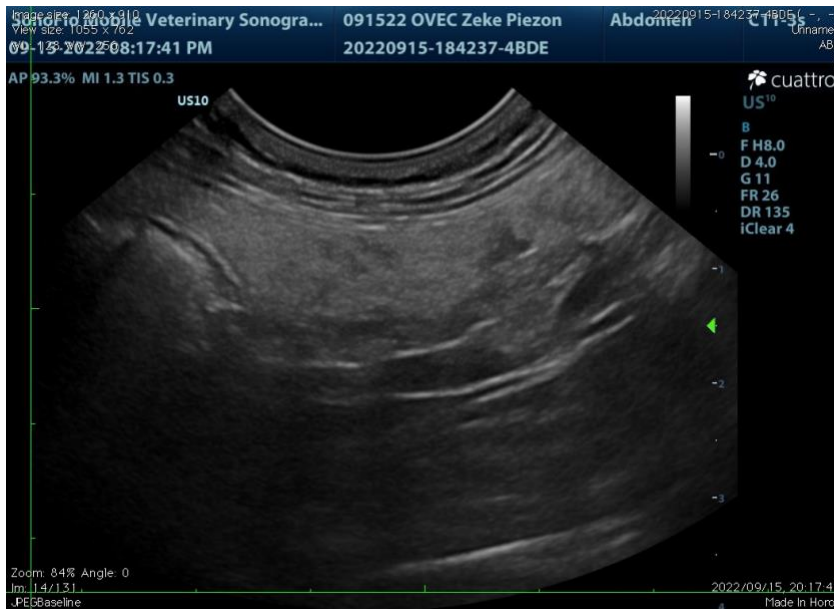Dr Gonzalez

INVOICE

303405

DATE

9/16/22





PATIENT **Liver**

Zeke Piezon

SPECIES

Feline

BREED

Siamese

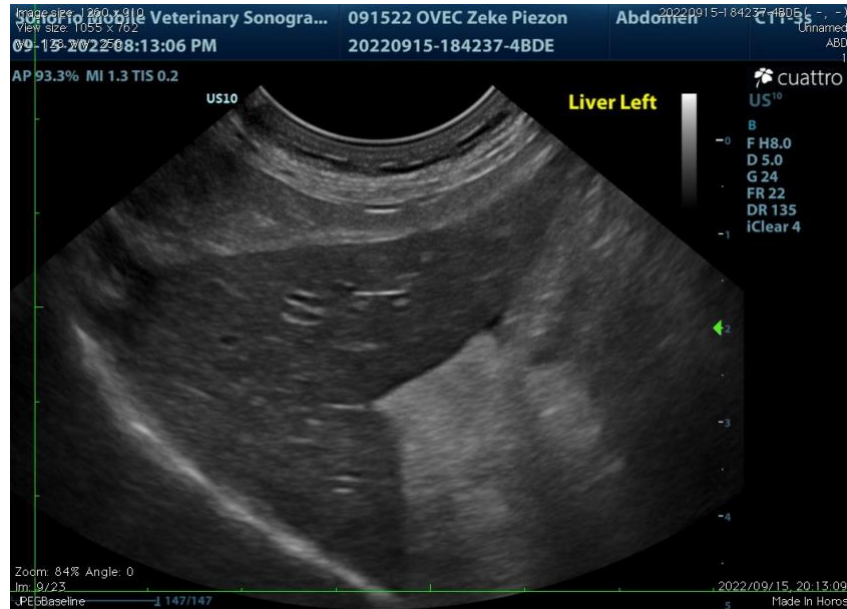SEX

FS

Age

14 years

WEIGHT



INTERPRETED BY

Remo Lobetti, BVSc,
 MMedVet (Med), PhD, Dipl.
 ECVIM

The information and recommendations provided are based on the images presented by the referring veterinarian. No evaluation can be communicated regarding pathology that was not visible in the image/video clips provided.

Thank you for this referral. If the clinical or image interpretation does not parallel your findings or if I can be of any further assistance, please contact me.

IMAGING PERFORMED BY

Sonya Myers, DVM

Remo Lobetti, BVSc, MMedVet (Med), PhD, Dipl. ECVIM (Internal Medicine)
rlobetti@mweb.co.za

HOSPITAL NAME

Oviedo Veterinary Care and
 Emergency

REFERRING VET

Dr Gonzalez

INVOICE

303405

DATE

9/16/22